



## Emerging pathology: pulmonary disease caused by *Mycobacterium xenopi* – a challenge in clinical practice

Urgentna patologija: bolest pluća prouzrokovana *Mycobacterium xenopi* – izazov u kliničkoj praksi

Dragica P. Pešut\*<sup>†</sup>, Ruža S. Stević\*<sup>‡</sup>, Jasmina Dj. Marić-Živković<sup>†</sup>,  
Biljana Dj. Savić<sup>†</sup>, Ljudmila M. Nagorni-Obradović\*<sup>†</sup>

University of Belgrade, \*Faculty of Medicine, Belgrade, Serbia; Clinical Centre of Serbia, <sup>†</sup>Teaching Hospital of Pulmonology, <sup>‡</sup>Centre of Radiology and Magnetic Resonance, Belgrade, Serbia

### Abstract

**Introduction.** Human nontuberculous *mycobacteria* (NTM) or environmental *mycobacteria* related disease is on increase. Risk factors are unclear and associations are observed in relation to climate differences, population density, or host susceptibility. With availability of molecular techniques for NTM identification, we faced emergence of NTM pulmonary cases. The work is an invitation more to colleagues to enroll the rare NTM cases into large study group. **Case report.** During an episode of productive cough and fever in a 73-year-old HIV-negative man smoker with minimal sequelae of pulmonary tuberculosis, sputum smears were acid fast bacilli positive on direct microscopy. The Löwenstein-Jensen culture results were positive with 20, 30 and 50 colonies, and molecular identification confirmed *Mycobacterium xenopi* (*M. xenopi*). Standard chest radiography showed no signs of active lesions. Examination was completed with bronchoscopy and thorax multi-slice computed tomography (MSCT). Cavitory lesions in the apico-posterior part of the

left upper lobe (LUL) were detected. Under treatment (rifampicin, ethambutol, clarithromycin) sputum conversion was achieved, but irregular cavitation in the LUL remained at MSCT after 6 and after 12 months with signs of minimal regression. Patient's general condition only mildly improved and asthenia remained. Observed risk factors were previous pulmonary disease, tobacco smoking, malnutrition and prolonged emotional stress. **Conclusion.** *M. xenopi* related pulmonary disease, difficult to cure and with uncertain prognosis, is a challenge in clinical practice. Since treatment is still controversial, more randomized clinical trials are needed. Current international multicentre approach might be a good option for a larger sample size and development of new guide.

### Key words:

lung diseases; mycobacterium xenopi; risk factors; diagnosis; drug therapy, combination; antibiotics; treatment outcome.

### Apstrakt

**Uvod.** Broj obolelih od bolesti izazvanih netuberkuloznim mikobakterijama (NTM) – mikobakterijama iz okoline, je u porastu. Faktori rizika za pojavu ovih bolesti nisu jasni, a uočene su razlike zavisno od klime, gustine naseljenosti i predispozicije ljudskog organizma. Većoj izolaciji uzročnika doprinosi i dostupnost molekularnih tehnika za njihovu identifikaciju. Ovaj rad je poziv kolegama da svoje retke pojedinačne slučajeve priključe u veliku studijsku grupu. **Prikaz bolesnika.** Povodom epizode produktivnog kašlja i febrilnosti, u tri uzorka sputuma 73-godišnjeg HIV-negativnog bolesnika, dugogodišnjeg pušača sa minimalnim

sekvelama plućne tuberkuloze, nađeni su acido-alkoholo-rezistentni bacili direktnom mikroskopijom. Rezultati kulture Löwenstein-Jensen bili su pozitivni sa 20, 30 i 50 kolonija, a molekularna identifikacija je potvrdila *Mycobacterium xenopi* (*M. xenopi*). Kako je standardni radiogram grudnog koša bio bez znakova aktivnih lezija, ispitivanje je dopunjeno bronhoskopijom i multi-slajsnom kompjuterizovanom tomografijom (MSCT) toraksa. Otkrivene su ekskavirane promene u apikoposteriornom delu levog gornjeg režnja pluća. Pod terapijom (rifampicin, etambutol i klaritromicin) postignuta je konverzija sputuma, ali se nepravilna ekskavacija održavala na MSCT toraksa posle šest i posle 12 meseci uz znake minimalne regresije. Opšte stanje bolesnika je bilo

nepromenjeno, uključujući i asteniju. Faktori rizika u ovom slučaju su prethodna plućna bolest, pušenje, pothranjenost i produženi emotivni stres. **Zaključak.** Plućna bolest izazvana *M. xenopi* predstavlja izazov u kliničkoj praksi. Teško se leći i ima neizvesnu prognozu. Kako optimalni terapijski pristup još nije poznat, potrebna su dobro kontrolisana klinička ispitivanja. Uključivanje retkih pojedinačnih slučajeva u tekuću međunarodnu multicentričnu studiju do-

velo bi do velikog uzorka bolesnika i donošenja novih smernica korisnih za praksu.

**Ključne reči:**  
pluća, bolesti; *mycobacterium xenopi*; faktori rizika; dijagnoza; lečenje kombinovanjem lekova; antibiotici; lečenje, ishod.

## Introduction

The nontuberculous *mycobacteria* (NTM) comprise all *mycobacteria* which do not belong to the *Mycobacterium tuberculosis* complex. They are also known as environmental *mycobacteria* and *mycobacteria* other than tuberculosis (MOTT) as well as atypical, opportunistic or anonymous *mycobacteria*. Disease caused by NTM has gained increased attention, in part due to an assumed increase in its incidence worldwide since 2000<sup>1-3</sup>. Human NTM disease has typically pulmonary, skin and soft tissue, lymphatic and/or disseminated presentation. Having molecular techniques for NTM identification available in Serbia since the end of 2008, we also have observed such increase in our pulmonary clinical practice<sup>4</sup>.

In 1954, Timpe and Runyon<sup>5</sup> demonstrated that NTM were pathogenic and five years later, Runyon<sup>6</sup> established the first classification based on colony pigmentation and the growth rate. Many NTM species have been subsequently described and new *mycobacteria* are discovered regularly. Nowadays, the NTM are a group of more than 170 species of bacteria. Twenty-five species are found to be strongly associated with disease in humans<sup>7</sup>. They are ubiquitous in soil and water, and they exhibit varied pathogenicity. Factors associated with human NTM infection like climate differences, population density, or host factors are still unclear. Thoracic skeletal abnormalities, rheumatoid arthritis, and treatment with immunomodulatory drugs have been recently highlighted as possible host factors<sup>1</sup>. Only a few of the NTM (*Mycobacterium avium* complex – MAC, *Mycobacterium kansasii* – *M. kansasii*, *Mycobacterium xenopi* – *M. xenopi*, *Mycobacterium abscessus* – *M. abscessus* and *Mycobacterium malmoense* – *M. malmoense*) have a demonstrated pulmonary pathogenicity<sup>8</sup>.

The distribution of NTM species that are isolated from clinical samples differs strongly by region<sup>3,9</sup>. Worldwide distribution of different NTM from pulmonary samples in 2008 showed that *M. xenopi* comprises some 8% of the respiratory NTM isolates on average, being 14% in Europe, and similarly, 12% in North America while no isolates were found in South America, Africa, Asia and Australia (Queensland)<sup>9</sup>. Increased rate of *M. xenopi* clinical isolation is reported with predominant respiratory specimens as the source<sup>10</sup>.

Diagnostic criteria for NTM disease have been established for few decades. Since the presence of NTM in one specimen is not sufficient to confirm lung infection, a crucial part of diagnostic procedure is to distinguish between colonization and infection/disease, which is not always easy.

In 1974, the American Thoracic Society (ATS) issued the first diagnostic criteria for NTM disease<sup>11</sup>, and in 1990 these became more restrictive<sup>12</sup>. Adapted later, they include clinical, radiographic, and bacteriologic criteria<sup>13</sup>. Only repeated isolation of the same NTM and the combination with particular clinical and radiological findings can provide sufficient support to diagnose true NTM disease.

Clinical picture of *M. xenopi* pulmonary disease is characterized by presence of respiratory symptoms in the vast majority of subjects at the time of diagnosis<sup>14,15</sup>. In a half of the patients, the disease has an onset of a subacute illness developing during 2 to 4 months, usually with increasing cough and sputum production, weight loss, and malaise. Radiographic changes may vary and were believed to be predominantly cavitory lesions<sup>15</sup>. The majority of patients with *M. xenopi* in a recent study had computed tomography (CT) patterns of random nodules or consolidation and/or ground-glass opacities rather than classically described findings<sup>16</sup>.

The treatment of pulmonary disease caused by NTM is controversial<sup>15</sup>. It is still uncertain whether *in vitro* drug sensitivity testing predicts clinical response in the way it does for *M. tuberculosis*. The results of susceptibility tests performed by the modal resistance method did not correlate with the patient's response to chemotherapy. Some literature data suggested that the combination of rifampicin and ethambutol was important whereas isoniazid might not be. In 1999, German authors reported a case of *M. xenopi* related pulmonary disease with sputum conversion achieved by the combination of clarithromycin, rifabutin and sparfloxacin<sup>17</sup>. Sparfloxacin is highly active against *mycobacteria*, but the use in clinical practice is restricted by its side effects. The British Thoracic Society has conducted the first trial, a randomized study of two regimens in HIV- negative patients with pulmonary disease caused by *M. avium intracellulare*, *M. malmoense*, and *M. xenopi*<sup>18</sup>. Contrary to previous suggestions that pulmonary disease with *M. xenopi* was relatively easy to treat and that it carried a good prognosis, nowadays it is considered as an illness difficult to cure and with uncertain prognosis<sup>8,19</sup>. The first results with *in vitro* susceptibility patterns to rifampicin, isoniazid, and streptomycin varied and were inconsistent, although the organisms were sensitive to cycloserine and ethionamide whenever tested<sup>8</sup>. Clarithromycin and moxifloxacin may have similar activity within treatment regimens for *M. xenopi* disease<sup>20</sup>. Future studies *in vitro* and *in vivo* are needed. Failure to treatment in many cases made it necessary to perform new prospective comparative randomized study<sup>21</sup>.

The authors aimed to highlight the emerging pathology, describe and discuss an example of *M. xenopi* caused pulmonary disease from current clinical practice.

### Case report

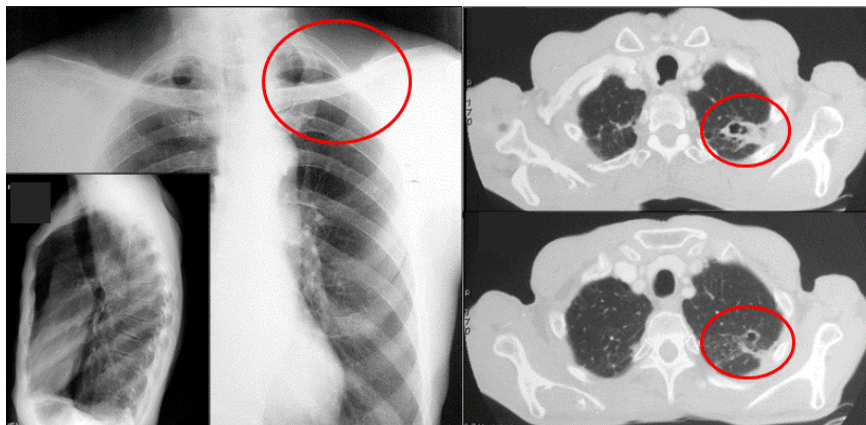
A 73-year-old HIV-negative man smoker without history of previous pulmonary disease, asked for medical care due to productive cough and fever of three-week duration. History taking revealed a loss of appetite and weight during previous several months together with prolonged emotional stress. His general condition has markedly worsened with malaise.

The patient's vital signs on admission were as follows: blood pressure 110/70 mmHg, body temperature 36.4°C, respiratory rate 18 breaths·min<sup>-1</sup>, pulse and heart rates: 88 beats·min<sup>-1</sup>, and oxygen saturation 95%, while breathing room air. The thorax physical examination showed findings that fitted an asthenic subject. Laboratory results of the peripheral blood and urine were within normal limits, except for mild thrombocytopenia [ $119 \times 10^9/L$  (normal lower value  $140 \times 10^9/L$ )]. White blood cells (WBC) range was normal:  $6.23 \times$

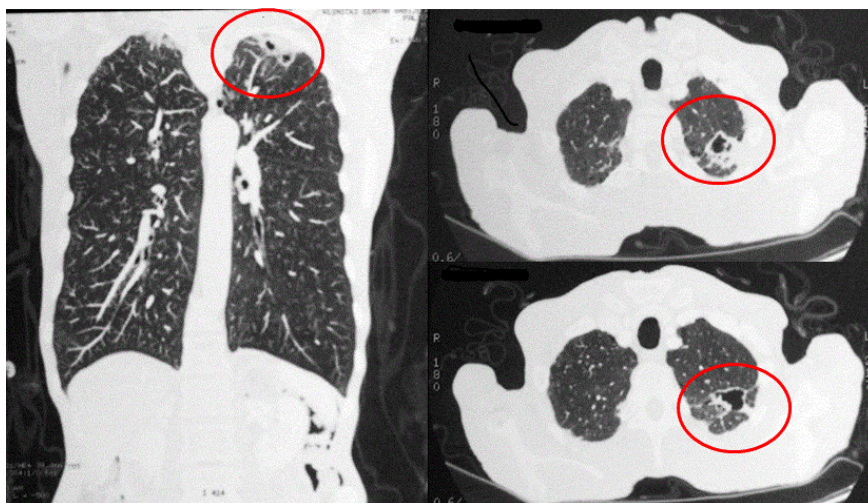
$10^9/L$  with 64.8% of neutrophils and 25.13% of lymphocytes.

Minimal sequellae of pulmonary tuberculosis were found on chest x-ray, and sputum smears were found to be acid-fast bacilli positive on direct microscopy. The Löwenstein-Jensen culture results were positive with 20, 30 and 50 colonies, and molecular identification confirmed *M. xenopi* [GenoType® *MTBC* (Hain)]. Since standard chest posteroanterior and left lateral projection radiographies showed no signs of active pulmonary disease, examination was completed with bronchoscopy and thorax multi-slice computed tomography (MSCT). Cavitory lesions in the apico-posterior part of the left upper lobe (LUL) were detected (Figure 1).

Under treatment (rifampicin, ethambutol, clarithromycin), sputum conversion was achieved within a month, but irregular fibrocavitary opacity in the LUL remained at MSCT after 6 and after 12 months with signs of minimal regression (Figure 2). The patient's general condition was mildly improved. The 18-month treatment was interrupted after 12 months following the patient's decision. Observed risk factors were previous pulmonary disease, tobacco smoking, malnutrition and prolonged emotional stress.



**Fig. 1 – Computed tomography scan (right) on admission shows irregular fibrocavitary opacity of the left upper lobe apicoposterior part in the presence of normal chest radiographies in frontal and lateral position (left).**



**Fig. 2 – Chest computed tomography, coronal (left) and axial (right) scans, after six-month treatment – still existing irregular fibrocavitary opacities with thinner cavity wall.**



## Discussion

We presented a rare case of *M. xenopi* caused pulmonary disease in a HIV-negative patient hospitalized in our tertiary level health care facility. After MAC and *Mycobacterium gordonae*, *M. xenopi* was the third most frequently isolated species in a recent worldwide survey, though its isolation was limited to distinct geographical regions, mainly in Europe and Ontario, Canada<sup>9</sup>. *M. xenopi* was more frequently isolated in Southern (21% of isolates) compared to Northern Europe (6% of isolates) partly due to substantial contribution of *M. xenopi* isolated in a single country. Interestingly, in Hungary, the country which is a north neighbour of Serbia, *M. xenopi* is the predominant NTM isolate comprising 49% of all the NTM<sup>9</sup>. In the same study, *M. xenopi* was the second most frequently isolated NTM, after *M. gordonae*, in neighbouring Croatia. We lack a report on such NTM distribution analysis in Serbia. Although the distribution may vary within the same country, based on the data on high proportion of *M. xenopi* isolates in two neighbouring countries, we assume that *M. xenopi* might present an important emerging pulmonary pathogen in Serbia as well. The recent cases from our clinical practice speak in favour of it.

Diagnostic criteria, which are necessary to distinguish *M. xenopi* active disease from a casual contaminant without a clinical significance were fulfilled in the presented case<sup>13</sup>. We obtained multiple isolations of *M. xenopi* from the sputum samples. Sputum smears were acid-fast bacilli positive on direct microscopy, three cultures positive, and *M. xenopi* proved by molecular technique in the absence of concurrent isolates of other pathogens, including *M. tuberculosis*. Finally, the symptomatic patient had abnormal chest MSCT consistent with mycobacterial disease. In a half of the patients with *M. xenopi* pulmonary disease, initial pulmonary radiographic changes are unilateral and cavitory changes are present in 96%<sup>15</sup>. While our finding is in concordance with this classical presentation of fibrocavitory disease, a recent study highlighted marked proportion of nodular pattern changes, which were also present in the latest Japanese case report, suggesting dissemination of the disease in an immunocompromised patient under steroid treatment<sup>16,22</sup>.

In 1994, Terashima et al.<sup>23</sup> reported two cases of pulmonary disease caused by *M. xenopi* – one occurred after gastrectomy and the other synchronously with *M. tuberculosis* infection, both presented with features of an infectious disease and unilateral cavitory lesion at chest x-rays<sup>23</sup>. Several cases of Japanese authors have been reported thereafter<sup>22,24</sup>. While all the firstly mentioned isolates were susceptible to streptomycin and kanamycin, the later results highlighted importance of drug susceptibility testing on disease outcome and levofloxacin as potential antibiotic with proven *M. xenopi* susceptibility in the presented cases<sup>24</sup>. Due to many challenges in therapy of *M. xenopi* pulmonary disease in recent years, an international study has been launched to assess the validity of two currently suggested three-drug therapy regimens: rifampicin + ethambutol and moxifloxacin or clarithromycin as the third one (CaMoMy study)<sup>21</sup>. We started therapy with available combined clarithromycin regimen and achieved sputum conversion in a month together with marked clinical improvement, but only mild radiographic regression over 12-month period.

Clinical picture of *M. xenopi* pulmonary disease in our patient was characterized by usual presence of general (weight loss, malaise) and respiratory symptoms (cough with sputum production) at the time of diagnosis. Sometimes, longer histories of respiratory symptoms, often present for several years, associated with slowly progressive changes on chest radiographs are seen. Hemoptysis is not a common sign. Only rarely, the disease appears as an acute illness characterized by repeated hemoptysis and weight loss occurring over a few weeks or as an asymptomatic disease discovered on regular physical examination or after mass miniature radiography<sup>8</sup>.

Since the prognosis in *M. xenopi* pulmonary disease is unpredictable with drug treatment alone, there would seem to be a good argument for lung resection in some patients, particularly in those who fail to respond initially to chemotherapy or who relapse<sup>8</sup>. For the same reason, prevention measures of NTM disease are under further investigation. Thus, the factors implicated in increased susceptibility to NTM pulmonary disease are also in the focus of current research. They may be local or systemic, congenital or acquired<sup>25</sup>. Our patient had a history of tobacco smoking, prolonged emotional stress, malnutrition, and sequelae tuberculosis as underlying condition. In many of the patients with NTM pulmonary disease in Europe, no underlying lung disease or immunodeficiency condition have been detected<sup>26</sup>.

NTM usually require abnormal airway mucosa to initiate bronchopulmonary infection. Local factors that exacerbate damage to the mucosal surface, or that increase the tissue burden of NTM, may promote disease. These include airway inflammation, ciliary dysfunction, abnormal sputum composition, mucus plugging of large or small airways, and the elongated bronchi, the majority present in our patient, a long-term heavy smoker. Apart from local irritation and inflammation, tobacco smoking contents are proved to decrease both cellular and humoral immunity in humans<sup>27</sup>. If it seems acceptable and evidence based that strengthening measures of tobacco control may have an additional and beneficial impact on tuberculosis elimination<sup>28</sup>, they might have an impact on the prevention of NTM pulmonary disease as well.

## Conclusion

Clinicians' awareness should be kept on the NTM related disease as an emerging pathology increasingly recognized in subjects with and without immunodeficiency. Increased detection rates of both slowly and rapidly growing NTM in pulmonary samples require careful estimation of diagnostic criteria for the NTM caused pulmonary disease and implementation of preventive measures. Treatment options need further estimation through new clinical trials aimed to develop a useful guide in current clinical practice.

## Acknowledgement

The paper was supported by the Ministry of Education, Science and Technological Development of the Republic of Serbia through contract No 175095.

## R E F E R E N C E S

1. *Prevots RD, Marras TK.* Epidemiology of human pulmonary infection with nontuberculous mycobacteria: A review. *Clin Chest Med* 2015; 36(1): 13–34.
2. *Thomson RM.* Changing epidemiology of pulmonary nontuberculous mycobacteria infections. *Emerg Infect Dis* 2010; 16(10): 1576–83.
3. *Marras TK, Daley CL.* Epidemiology of human pulmonary infection with nontuberculous mycobacteria. *Clin Chest Med* 2002; 23(3): 553–67.
4. *Stjepanović MI, Pešut DP, Lešić AR, Stević RS.* Pulmonary and Vertebral Mycobacterium avium Disease in a HIV-negative 71-year-old Man A Case Report. *Infez Med* 2016; 24(4): 345–8.
5. *Timpe A, Runyon EH.* The relationship of atypical acid-fast bacteria to human disease: A preliminary report. *J Lab Clin Med* 1954; 44(2): 202–9.
6. *Runyon EH.* Anonymous mycobacteria in pulmonary disease. *Med Clin North Am* 1959; 43(1): 273–90.
7. *van Ingen J.* Diagnosis of nontuberculous mycobacterial infections. *Semin Respir Crit Care Med* 2013; 34(1): 103–9.
8. *Griffith DE, Aksamit T, Brown-Elliott BA, Catanzaro A, Daley C, Gordin F, et al.* An official ATS/IDSA statement: diagnosis, treatment, and prevention of nontuberculous mycobacterial diseases. *Am J Respir Crit Care Med* 2007; 175(4): 367–416.
9. *Hoefsloot W, van Ingen J, Andrejak C, Angeby K, Bauriaud R, Bemer P, et al.* The geographic diversity of nontuberculous mycobacteria isolated from pulmonary samples: an NTM-NET collaborative study. *Eur Respir J* 2013; 42(6): 1604–13.
10. *Bluth MH, Vera R, Razeg J, Kramer M, Abu-Lawi KI.* Mycobacterium xenopi: Evidence for Increased Rate of Clinical Isolation. *Int J Biomed Sci* 2009; 5(2): 96–100.
11. *American Thoracic Society.* Diagnostic standards and classification of tuberculosis and other mycobacterial diseases. New York: American Lung Association; 1974.
12. *Wallace RJ Jr, O'Brien R, Glassroth J, Raleigh J, Dutt A, American Thoracic Society.* Diagnosis and treatment of disease caused by nontuberculous mycobacteria. *Am Rev Respir Dis* 1990; 142(4): 940–53.
13. *Medical Section of the American Lung Association.* Diagnosis and treatment of disease caused by nontuberculous mycobacteria. This official statement of the American Thoracic Society was approved by the Board of Directors, March 1997. *Am J Respir Crit Care Med* 1997; 156(2 Pt 2): S1–25.
14. *van Ingen J, Bendien SA, de Lange WCM, Hoefsloot W, Dekhuijzen PNR, Boeree MJ, et al.* Clinical relevance of non-tuberculous mycobacteria isolated in the Nijmegen-Arnhem region, The Netherlands. *Thorax* 2009; 64(6): 502–6.
15. *Banks J, Hunter AM, Campbell LA, Jenkins PA, Smith AP.* Pulmonary infection with Mycobacterium xenopi: Review of treatment and response. *Thorax* 1984; 39(5): 376–82.
16. *Carrillo MC, Patsios D, Wagnetz U, Jamieson F, Marras TK.* Comparison of the spectrum of radiologic and clinical manifestations of pulmonary disease caused by Mycobacterium avium complex and Mycobacterium xenopi. *Can Assoc Radiol J* 2014; 65(3): 207–13.
17. *Schmitt H, Schnitzler N, Riehl J, Adam G, Sieberth HG, Haase G.* Successful treatment of pulmonary Mycobacterium xenopi infection in a natural killer cell-deficient patient with clarithromycin, rifabutin, and sparflaxacin. *Clin Infect Dis* 1999; 29(1): 120–4.
18. *Research Committee of the British Thoracic Society.* First randomised trial of treatments for pulmonary disease caused by M avium intracellulare, M malmoense, and M. xenopi in HIV negative patients: Rifampicin, ethambutol and isoniazid versus rifampicin and ethambutol. *Thorax* 2001; 56(3): 167–72.
19. *Dauendorffer JN, Laurain C, Weber M, Dailoux M.* In vitro sensitivity of Mycobacterium xenopi to five antibiotics. *Pathol Biol (Paris)* 2002; 50(10): 591–4.
20. *Ferro BE, van Ingen J, Wattenberg M, van Soolingen D, Mouton JW.* Time-kill kinetics of slowly growing mycobacteria common in pulmonary disease. *J Antimicrob Chemother* 2015; 70(10): 2838–43.
21. *Andrejak C.* (PI) Treatment of M. xenopi infections (CaMoMy Trial) TBnet #34 / NTM-NET #5. [cited 2015 Dec 15]. Available from: <http://www.tb-net.org/index.php/tbnet-research/ongoing-projects>
22. *Okano Y, Shinohara T, Imanishi S, Takahashi N, Naito N, Taoka T, et al.* Miliary pulmonary nodules due to Mycobacterium xenopi in a steroid-induced immunocompromised patient successfully treated with chemotherapy: A case report. *BMC Pulm Med* 2016; 16(1): 92.
23. *Terashima T, Sakamaki F, Hasegawa N, Kanazawa M, Kawashiro T.* Pulmonary Infection due to Mycobacterium xenopi. *Int Med* 1994; 33(9): 536–9.
24. *Matsui Y, Tamura A, Nagayama N, Akashi S, Araki K, Kimura H, et al.* Review of pulmonary Mycobacterium xenopi infection cases: 11 cases of our own and 18 other cases reported in Japan. *Kekkaku* 2010; 85(8): 647–53. (Japanese)
25. *Sexton P, Harrison AC.* Susceptibility to nontuberculous mycobacterial lung disease. *Eur Respir J* 2008; 31(6): 1322–33.
26. *Wassilew N, Hoffmann H, Andrejak C, Lange C.* Pulmonary Disease Caused by Non-Tuberculous Mycobacteria. *Respiration* 2016; 91(5): 386–402.
27. *Sopori M.* Science and society: Effects of cigarette smoke on the immune system. *Nat Rev Immunol* 2002; 2(5): 372–7.
28. *Zellweger JP, Cattamanchi A, Sotgiu G.* Tobacco and tuberculosis: Could we improve tuberculosis outcomes by helping patients to stop smoking? *Eur Respir J* 2015; 45(3): 583–5.

Received on December 24, 2015.

Revised on December 19, 2016.

Accepted on December 20, 2016.

Online First February, 2017.